

PennHIP Report

Referring Veterinarian: Dr Brian Keller

Clinic Name: Countryside Veterinary Clinic (WI)

Email: countrysidevet@frontiernet.net

Clinic Address: 1231 N Knowles Ave
New Richmond, WI 54017

Phone: (715) 246-5606

Fax: (715) 246-9256

Patient Information

Client: Rasmussen, Brianna

Tattoo Num:

Patient Name: Hilde

Patient ID: 16357Hilde

Reg. Name: Hilde Of The Kinni

Registration Num: SS24183005

PennHIP Num: 158410

Microchip Num: 933000320385045

Species: Canine

Breed: GOLDEN RETRIEVER

Date of Birth: 12 Jan 2021

Age: 5 months

Sex: Female

Weight: 38.4 lbs/17.4 kgs

Date of Study: 16 Jun 2021

Date Submitted: 16 Jun 2021

Date of Report: 21 Jun 2021

Findings

Distraction Index (DI): Right DI = 0.40, Left DI = 0.38.

Osteoarthritis (OA): **No radiographic evidence of OA for either hip.**

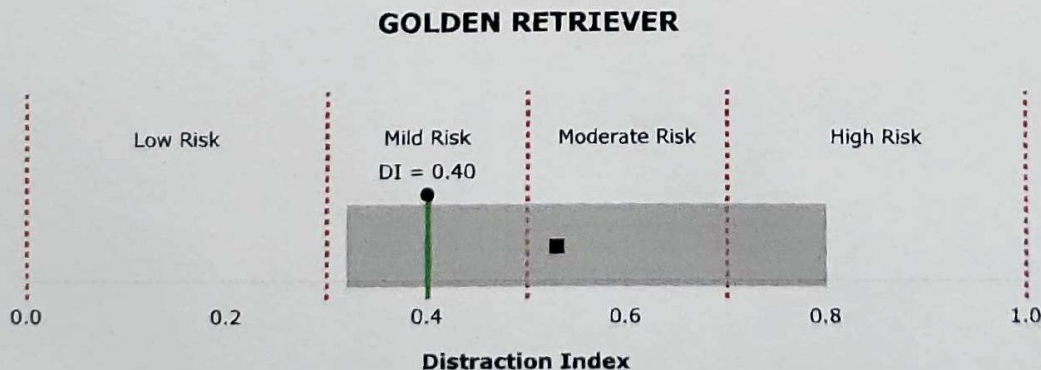
Cavitation/Other Findings: No cavitation present.

Interpretation

Distraction Index (DI): The laxity ranking is based on the hip with the greater laxity (larger DI). In this case the DI used is 0.40.

OA Risk Category: The DI is between 0.31 and 0.49. This patient is at mild risk for hip OA.

Distraction Index Chart:



BREED STATISTICS: This interpretation is based on a cross-section of 22560 canine patients of the GOLDEN RETRIEVER breed in the AIS PennHIP database. The gray strip represents the central 90% range of DIs (0.32 - 0.80) for the breed. The breed average DI is 0.53 (solid square). The patient DI is the solid circle (0.40).

SUMMARY: The degree of laxity (DI = 0.40) falls within the central 90% range of DIs for the breed. This amount of hip laxity places the hip at a mild risk to develop hip OA. **No radiographic evidence of OA for either hip.**